

Clinical and Haematological Characteristics of Haemoglobin H Disease

ASMA REHMAN¹, SUHAIB AHMED², USMAN ANSARI³

ABSTRACT

Aim: To study the clinical and haematological characteristics of haemoglobin H disease

Study design: Descriptive cross sectional study.

Place & duration: The study was conducted at the department of Haematology, Armed Forces Institute of Pathology (AFIP), Rawalpindi, over a period of five years.

Methods: By using non probability consecutive sampling, we assessed the clinical features and haematological values of the patients visiting AFIP for hemoglobin studies. Complete blood counts were done on Sysmex KX 21 automated haematology analyzer. Haemoglobin H inclusions were visualized by supra vital staining with New methylene blue. Hemoglobin electrophoresis of the sample was carried out on cellulose acetate membrane in Tris EDTA borate buffer at 8.9pH.

Results: Against 557 patients diagnosed as Thalassaemia Major/ Intermedia, Haemoglobin H disease was diagnosed in 10 patients during the study period. Out of the ten patients 4(40%) were males while 6(60%) were females. The patients ranged in age from 7 to 32 years. 60% were Punjabi and 40% were Pathan. Clinical presentation of the patients was symptoms of anaemia in 100% and jaundice in 10%. History of transfusion was present in 90% of the patients. On examination pallor was present in 100%, liver was palpable in 20% and spleen in 80% cases. Mean haematological parameters were TRBC 4.5(±1.6), Hb 8.8(±2.2), MCV 71.9(±11.8), MCH 20.4(±2.9), MCHC 25.7(±8.7). Mean reticulocyte count was 15.8%(±9.4). Haemoglobin H inclusions were seen in 100% cases. Band of Haemoglobin H was seen on cellulose acetate membrane in all of the patients.

Conclusion: Haemoglobin H disease is an uncommon disorder and out of 557 Thalassaemia major/Intermedia patients diagnosed during this period 10(1.7%) patients were diagnosed as having Haemoglobin H disease.

Keywords: Haemoglobin H disease, α -thalassaemia, unstable haemoglobin

INTRODUCTION

α -thalassaemia is the most common hereditary disorder found in Southeast Asia and China¹. It is a disorder of haemoglobin synthesis resulting from deletions or mutations (or both) of α -globin genes, located on short arm of chromosome 16². There are four α -globin genes in normal genome (two on each chromosome) and the clinical presentation of the genetic abnormalities range from a silent carrier state, with a single α -globin gene deletion, to Hydrops fetalis, in which all four α -globin genes are deleted³. Haemoglobin H disease is a thalassaemia of intermediate severity in which three of the four α -globin genes are affected and is characterized by the presence of an abnormal haemoglobin, Haemoglobin H⁴. In majority of cases it results from compound heterozygosity for α^+ -thalassaemia and α^0 -thalassaemia (genotype - - / - α). However, it may

also result from interactions between α^0 -thalassaemia deletional mutations (usually a point mutation) involving the α -globin gene ($\alpha^1\alpha$ or α^-)⁵.

The haemoglobin molecule is a tetramer, consisting mostly of two α -globin genes and two β -globin genes which forms 'haemoglobin A' component of the adult haemoglobin.

Balanced production of these globin chains is important for the formation of normal haemoglobin and the integrity of erythrocytes^{3, 6}.

Haemoglobin H disease is characterized by reduced synthesis of α -globin chains with resultant excess of β -globin chain within the erythroblasts and erythrocytes. This leads to formation of abnormal haemoglobin with β -globin chain tetramers, referred to as Haemoglobin H. These tetramers are unstable and precipitate in erythroblasts/erythrocytes causing lysis of these cells^{1, 7}.

Patients with Haemoglobin H may present clinically with symptoms of anaemia and hepatosplenomegaly, or may be found incidentally to have a hypochromic microcytic anaemia^{7, 8}. Most patients are classified as 'Thalassaemia Intermedia' with baseline haemoglobin level between 8 –10 g/dl having compensated hemolytic anaemia. These

¹Assistant Professor Pathology, Aziz Fatimah Medical And Dental College, Faisalabad.

²GRC Lab, Rawalpindi.

³Asst Prof.r Pathology, Independent Medical College, Faisalabad.

Correspondence to Dr. Asma Rehman, Email: dr.asmarehman@gmail.com Cell: 0333-5134290a

patients have mild or absent hepatosplenomegaly and no requirement for regular blood transfusion^{6,9}. α -thalassaemia is a common genetic disorder in Pakistan. However a comprehensive data on Haemoglobin H disease is not available for our population. In this study we present the clinical and haematological characteristics of haemoglobin H disease in Pakistani patients.

MATERIALS AND METHODS

This descriptive cross-sectional study was conducted at the Department of Haematology, Armed Forces Institute of Pathology, Rawalpindi. The study was conducted over a period of five years. All the individuals who were part of the study were selected by non probability consecutive sampling.

The patients were assessed for the clinical features. The following were determined: age at diagnosis, symptoms at presentation, and transfusion history. Each patient underwent a physical examination for the presence or absence of pallor and jaundice, and the size of the spleen and liver were determined.

Five ml of venous blood was drawn from antecubital vein by aseptic technique and collected in EDTA. Complete blood counts were performed on Sysmex KX 21 automated haematology analyzer within 1-3 hours of collection of blood. The haematological parameters assessed were TRBC, Hb, MCV, MCH and MCHC. Haemoglobin H inclusions were visualized microscopically, by supra vital staining of red cells with New methylene blue at 37°C for 1-2 hours and making blood films.

Hemolysate was prepared from washed red blood cells and haemoglobin electrophoresis of the sample was carried out on cellulose acetate membrane in Tris EDTA borate buffer at pH 8.9. Visual assessment of the bands of Hemoglobin H of the patients was done by comparing with normal control.

RESULTS

During this period a total of 557 patients of Beta Thalassaemia Major/ Intermedia were diagnosed. Against these 557 patients 10 patients were diagnosed as Haemoglobin H disease, out of which 4 (40%) were males while 6(60%) were females. The age of the patients ranged between 7 and 32 years with a median age of 17±08 years. 60% were Punjabi and 40% were Pathan.

Clinical presentation of the patients was symptoms of anaemia 100% and jaundice 10%. History of transfusion was present in 90% of the patients, but they were not transfusion dependant. On examination pallor was present in 100%, liver was palpable in 20% and spleen in 80% patients.

Mean haematological parameters obtained by the analyzer are presented in table 1. RBC morphology on peripheral film showed anisopoikilocytosis with hypochromia and microcytosis. Mean reticulocyte count was 15.8% (\pm 9.4). Haemoglobin H inclusions were seen in 100% cases by supra vital staining with New methylene blue (Fig. 1). Fast moving band of Haemoglobin H was visualized on cellulose acetate membrane in all the patients (Fig. 2).

Fig. 1: Haemoglobin H inclusions

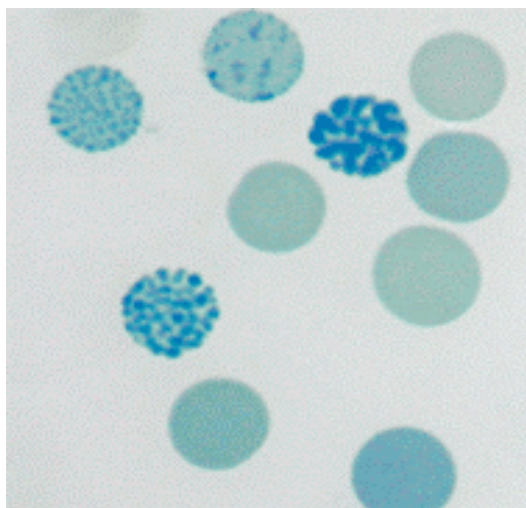


Fig. 2: Haemoglobin Electrophoresis on Cellulose acetate membrane at pH 7.9 shows fast moving band of Hb H.

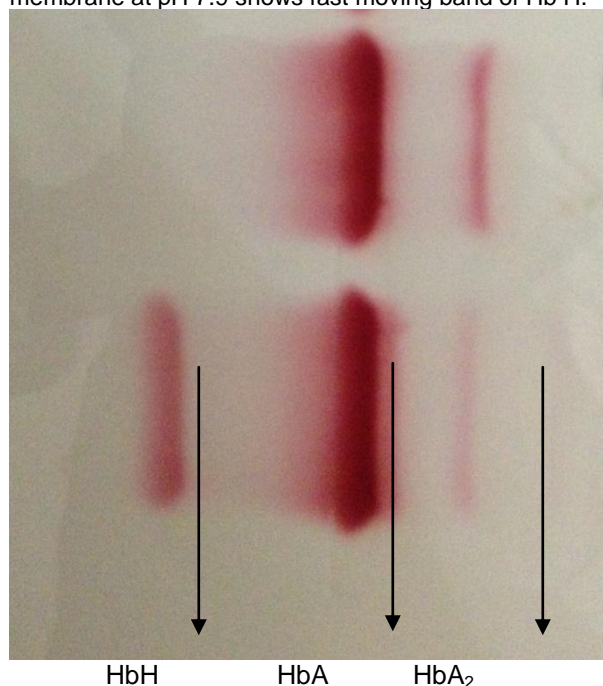


Table 1: Red blood cell parameters

RBC parameters	Mean values	St. deviation
TRBC (x 10 ¹² /L)	4.5	± 1.6
Hb (g/dl)	8.8	± 2.2
MCV (fl)	71.9	± 11.8
MCH (pg)	20.4	± 2.9
MCHC (g/dl)	25.7	± 8.7

DISCUSSION

α -thalassaemia is one of the most common single gene disorders affecting 5% of world's population. The prevalence of α^+ -thalassaemia in Pakistan is 15-20%, whereas that of α^0 -thalassaemia is not documented⁶. The high prevalence of α^+ -thalassaemia trait in Pakistan is the most likely reason for the low frequency of Haemoglobin H disease in this region.

Haemoglobin H disease is of intermediate clinical severity resulting from three α -globin gene deletions and/or mutations, presenting clinically as 'Thalassaemia Intermedia'^{1, 7}. There is considerable phenotypic variability of this disease, with some patients receiving repeated blood transfusions because of anaemia, and some patients having variable hepatosplenomegaly. These patients also develop iron overload progressively as they age, or due to repeated blood transfusions^{1,8}. Eight out of the 10 patients in our study had splenomegaly and 02 had hepatomegaly. Nine of them had been transfused once or twice but none of them was transfusion dependant.

Laboratory diagnosis of Haemoglobin H disease starts with a Blood complete picture showing hypochromic microcytic anaemia with a raised red cell distribution width due to anisopoikilocytosis, which is seen on peripheral film¹⁰. Red cell inclusion bodies are observed in the majority of RBC's after staining with supravital dyes such as methylene blue or brilliant cresyl blue¹¹. Haemoglobin H is detected as a fast moving band by electrophoresis of a freshly prepared hemolysate at alkaline pH and typically amounts to 3% to 30% of total haemoglobin^{4,12}. The diagnosis can be confirmed by DNA analysis by polymerase chain reaction (PCR).¹³ Our study shows that all of the 10 patients presented to us with hypochromic microcytic anaemia; with mean Hb 8.8 g/dl, mean MCV 71.9 fl and a mean MCH 20.4pg. Haemoglobin H inclusions were seen in 100% cases by supra vital staining with New methylene blue and a fast moving band of Haemoglobin H was visualized by electrophoresis in all the patients.

The phenotypic variability of Haemoglobin H disease depends on the mutational status of the patient, as it is generally known that the non-deletional Haemoglobin H disease is more severe than the deletional form of the disease.^{1, 7, 8} These

mutations can be diagnosed by molecular methods which are limited in Pakistan. The detection of the genetic mutation in the α -globin gene will aid in carrier detection, prenatal diagnosis, in predicting the clinical outcome of the patient and to improve genetic counseling of the couple at risk^{5,14,15}.

CONCLUSION

Haemoglobin H disease is an uncommon disorder. Against the 557 Beta Thalassaemia major/Intermedia patients diagnosed during this time period from Jan 2005 – Dec 2009, only 10(1.7%) patients were diagnosed as having Haemoglobin H disease. These patients present as chronic anaemia, occasional jaundice and splenic enlargement.

REFERENCES

- Chen F E, Ooj C, Ha S Y, Cheung B M, Todd D, Liang R, Chan T K, et al. Genetic and clinical features of Haemoglobin H disease in Chinese patients. *N Engl J Med* 2000; 343:544.
- Elliott P. Vichinsky. Alpha thalassaemia major--new mutations, intrauterine management, and outcomes. *Hematology Am Soc Hematol Educ Program* 2009:35-41.
- Thein S L, Rees D. Hemoglobin and the inherited disorders of globin synthesis. In: Hoffbrand A V, Catovsky D, Tuddenham E G D, Green A R. *Postgraduate haematology*. 6th ed. West Sussex: Wiley-Blackwell; 2011:83-108.
- Azarkeivan A, Neishabury M, Hadavi V, Esteghamat F, Enrahimkhani S, Najmabadi H. A report of 8 cases with hemoglobin H disease in an Iranian family. *Pediatr Hematol Oncol* 2010; 27:405-12.
- Chui D H. Alpha-thalassaemia: Hb H disease and Hb Barts hydrops fetalis. *Ann N Y Acad Sci* 2005; 1054:25-32.
- Bain B J. The α , β , δ and γ thalassaemias and related conditions. In: Bain B J. *Haemoglobinopathy Diagnosis* 2nd ed. Blackwell Publishing; 2006:79-87.
- Chui DH, Fucharoen S, Chan V. Haemoglobin H disease: not necessarily a benign disorder. *Blood* 2003; 101:791-800.
- Fucharoen S, Viprakasit V. Hb H disease: clinical course and disease modifiers. *Hematology Am Soc Hematol Educ Program* 2009: 26-34.
- Lorey F, Charoenkwan P, Witkowska H E, Lafferty J, Patterson M, Eng B et al. Hb H hydrops foetalis syndrome: a case report and review of literature. 2001; 115:72-78.
- Ma E S, Chan A Y, Au W Y, Yeung Y M, Chan L C. Diagnosis of concurrent hemoglobin H disease and heterozygous beta-thalassaemia. *Haematologica* 2001; 86:432-433.
- Wild B, Bain B J. Investigations of abnormal haemoglobins and thalassaemia. In: Lewis S M, Bain B J, Bates I (edi). *Dacie and Lewis Practical Haematology* 10th ed. Philadelphia: Elsevier Ltd; 2006:272-308.
- Old J M. Screening and genetic diagnosis of haemoglobinopathies. *Scand J Clin Lab Invest* 2007; 67:71.
- Weatherall D J. Current trends in the diagnosis and management of haemoglobinopathies. *Scand J Clin Lab Invest* 2007; 67:1-2.
- Henderson S, Pitman M, McCarthy J. Molecular prenatal diagnosis of Hb H hydrops fetalis caused by haemoglobin Adana and the implications to antenatal screening for alpha-thalassaemia. *Prenat Diagn* 2008; 28:859-861.
- Li D Z, Liao C, Li J, Xie X M, Huang Y N, Wu Q C. Hemoglobin H hydrops fetalis syndrome resulting from the association of the --SEA deletion and the alphaQuong Sze alpha mutation in a Chinese woman. *Eur J Haematol* 2005; 75:259-261.

